



Complete eye care
services in a comfortable
and caring environment.



Northern Eye

Robert M. Currier, D.O., FOCOO

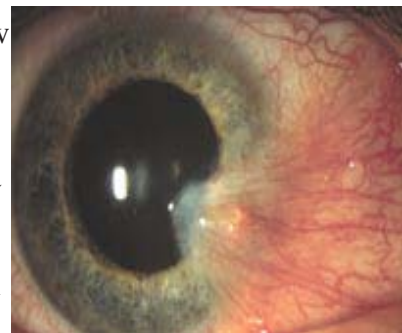127 PARK PLACE • ALPENA, MI 49707 • (989) 354-3171

205 S. Bradley Hwy. • Rogers City, MI 49779

Michigan and Nationwide Toll Free: 1-800-77-1015 • E-Mail: Northerneye@i2k.net

Pterygium and Pinguecula

A **pterygium** is fleshy tissue that grows over the cornea (the clear front window of the eye). It may remain small or may grow large enough to interfere with vision. A pterygium most commonly occurs on the inner corner of the eye, but can appear on the outer corner as well. The exact cause is not well understood. Pterygium occurs more often in people who spend a great deal of time outdoors, especially in sunny climates. Long-term exposures to sunlight, especially ultraviolet (UV) rays, and chronic eye irritation from dry, dusty conditions seem to play an important causal role. A dry eye may also contribute to pterygium.



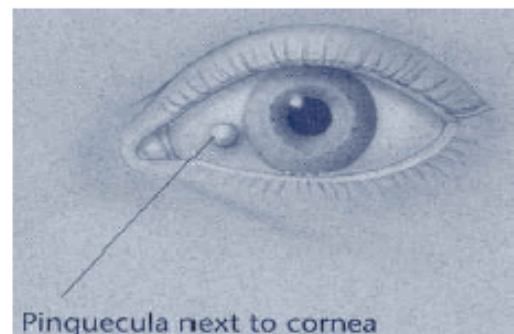
Pterygium of the eye

When a pterygium becomes red and irritated, eyedrops or ointments may be used to help reduce the inflammation. If the pterygium is large enough to threaten sight or grows rapidly, it can be removed surgically.

Despite proper surgical removal, the pterygium may return, particularly in young people. Protecting the eyes from excessive ultraviolet light with proper sunglasses and avoiding dry, dusty conditions and use of artificial tears may also help.

A **pinguecula** is a yellowish patch or bump on the white of the eye, most often on the side closest to the nose. It is not a tumor, but an alteration of normal tissue resulting in a deposit of protein and fat. Unlike a pterygium, a pinguecula does not actually grow onto the cornea. A pinguecula may also be a response to chronic eye irritation or sunlight.

No treatment is necessary unless it becomes inflamed. A pinguecula does not grow onto the cornea or threaten sight. If particularly annoying, a pinguecula may on rare occasions be surgically removed, but the postoperative scar may be as cosmetically objectionable as the pinguecula.



Pinguecula next to cornea

It is important for Dr. Currier to examine and diagnose a pinguecula or pterygium to ensure it is not something more serious.